

Technical Note

Open Access



Technique of robotic first rib resection for thoracic outlet syndrome

Farid Gharagozloo, Nabhan Atiquzzaman, Mark Meyer, Scott Werden

Center for Advanced Thoracic Surgery, Global Robotics Institute, Advent Health Celebration, University of Central Florida, Celebration, FL 34786, USA.

Correspondence to: Dr. Farid Gharagozloo, Center for Advanced Thoracic Surgery, Global Robotics Institute, Advent Health Celebration, University of Central Florida, 400 Celebration Place, Celebration, FL 34786, USA. E-mail: Gharagozloof@aol.com

How to cite this article: Gharagozloo F, Atiquzzaman N, Meyer M, Werden S. Technique of robotic first rib resection for thoracic outlet syndrome. *Mini-invasive Surg* 2021;5:39. <https://dx.doi.org/10.20517/2574-1225.2021.74>

Received: 7 Jun 2021 **First Decision:** 14 Jul 2021 **Revised:** 15 Jul 2021 **Accepted:** 23 Jul 2021 **First online:** 24 Jul 2021

Academic Editor: Giulio Belli **Copy Editor:** Yue-Yue Zhang **Production Editor:** Yue-Yue Zhang

Abstract

Conventionally, resection of the first rib has been performed by the transaxillary and supraclavicular approaches. These approaches are hampered by poor visualization and exposure of the operative field, neurovascular complications, and less than optimal surgical outcomes. The Robotic Surgical System allows for high-definition, magnified, three-dimensional visualization of the operative field and is associated with accurate instrument maneuverability in a confined space. Importantly, the robotic transthoracic technique facilitates the disarticulation of the costo-sternal joint, which appears to be the most critical determinant of surgical success. Robotic first rib resection has been associated with the best-reported outcomes in patients with both Neurogenic and Venous (Paget Schroetter Syndrome) Thoracic Outlet Syndrome (TOS). This paper outlines the technique of robotic first rib resection with disarticulation of the costo-sternal joint for patients with TOS.

Keywords: Robotic Surgery, first rib resection, thoracic outlet syndrome, neurogenic, venous, paget schroetter

INTRODUCTION

Thoracic Outlet Syndrome (TOS) is highly underdiagnosed and undertreated^[1]. It is estimated that TOS affects 0.3 to 8% of the population. This high variance in the reported prevalence reinforces the challenges in terms of understanding TOS. Any discussion about TOS always begins with the classification that dates back to the 1950s: Neurogenic (NTOS), Venous (Paget Schroetter Syndrome, PSS), and Arterial TOS^[2].



© The Author(s) 2021. **Open Access** This article is licensed under a Creative Commons Attribution 4.0 International License (<https://creativecommons.org/licenses/by/4.0/>), which permits unrestricted use, sharing, adaptation, distribution and reproduction in any medium or format, for any purpose, even commercially, as long as you give appropriate credit to the original author(s) and the source, provide a link to the Creative Commons license, and indicate if changes were made.



Over the years, due to the lack of objective findings in the majority of patients with NTOS, NTOS has been further classified as True NTOS and Disputed (NTOS). The majority of patients with TOS have NTOS, and the majority of patients with NTOS are in the “Disputed” category (DNTOS). Patients with DNTOS have neurologic symptoms such as pain and paresthesia in the upper extremity, neck and shoulder with a normal neurologic exam and nerve conduction studies. Historically, it has been thought that TOS results from the compression of the neurovascular structures in the upper chest and the neck. The first rib has been the common denominator in this hypothesis.

Recently Gharagozloo *et al.*^[3,4] have described a congenital malformation at the costo-sternal joint of the first rib as the “offending” pathologic entity in patients with PSS and DTNOS [Figures 1-4]. Using dynamic Magnetic Resonance Imaging and 3-D computerized tomography reconstruction, these authors have shown that with the elevation of the upper extremity and activity, the subclavian vein is compressed between the costo-sternal joint and the clavicle. They have hypothesized that in patients with DNTOS, neurologic symptoms may manifest nerve pain that results from venous compression and the resultant venous ischemia of the nerves in the upper extremity. This hypothesis is based on the fact that the upper extremity is fed by a single artery and vein as an “end organ”. Venous congestion may be an essential factor precipitating circulatory disturbance in nerve roots and inducing neurogenic intermittent claudication. Venous congestion has been shown to break the blood-nerve barrier and result in relative ischemia^[5]. As a proof of concept, these authors have demonstrated that in patients with persistent neurologic symptoms following first rib resection, the disarticulation of the costo-sternal joint, which was previously described as the costoclavicular ligament, has resulted in excellent relief of symptoms^[6-8]. Therefore, it is crucial to disarticulate the costo-sternal joint as part of first rib resection in patients with TOS. Also, these authors have shown that PSS is simply the manifestation of the same pathologic entity, which results in thrombosis with prolonged compression of the subclavian vein.

The most common first rib resection is performed using a transaxillary or supraclavicular approach. However, these approaches are associated with neurovascular complications, incomplete decompression of the subclavian vein and the medial aspect of the thoracic outlet, and difficulty in disarticulating the costo-sternal joint from outside the chest cavity.

The robotic surgical systems have the advantages of 3D visualization and precise instrument maneuverability in a confined space. The surgical robot has facilitated a precise, minimally invasive transthoracic approach to disarticulating of the costo-sternal joint and resection of the first rib. This approach has been associated with the best-reported results in patients with PSS and NTOS.

This communication outlines the technique of robotic first rib resection with disarticulation of the costo-sternal joint for patients with TOS.

TECHNIQUE OF ROBOTIC RESECTION OF THE MEDIAL ASPECT OF THE FIRST RIB AND DISARTICULATION OF THE COSTO-STERNAL JOINT

A video of the procedure is available at: <https://www.youtube.com/watch?v=2mCKcgAAjbs>

Patients are placed in the lateral decubitus position with the affected side up with single lung ventilation of the ipsilateral side. The procedure is performed in 5 steps.

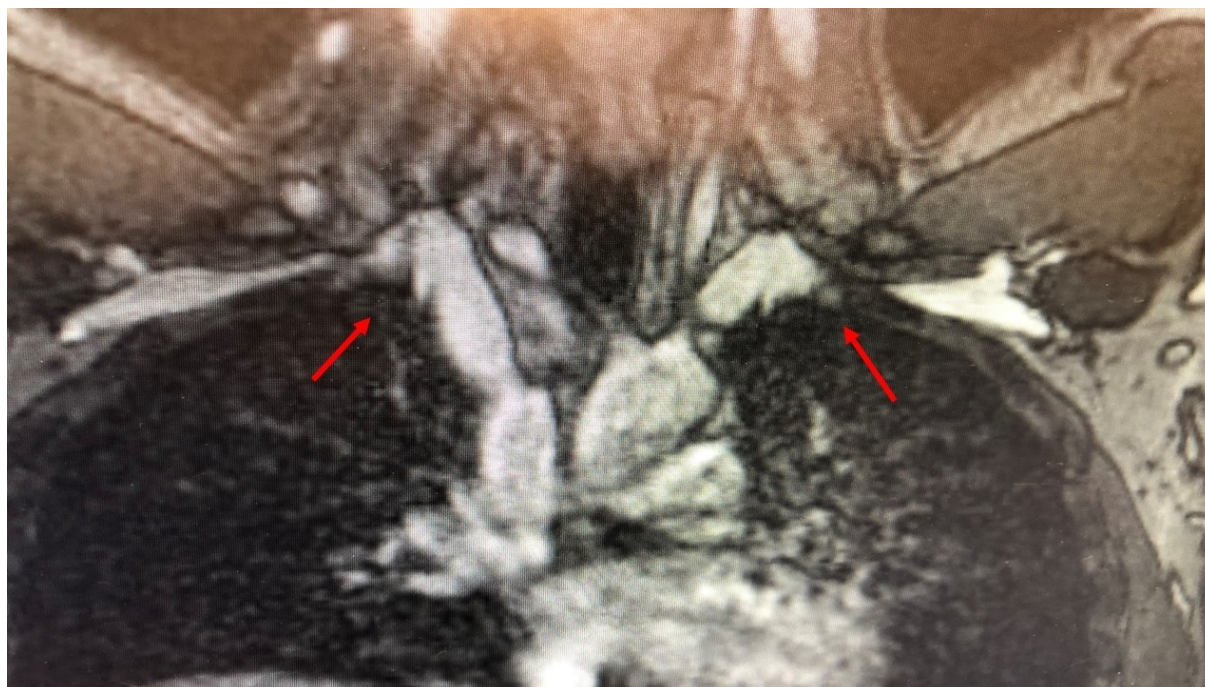


Figure 1. Magnetic Resonance Angiogram with elevation of the arms in a patient with PSS. There is bilateral compression off the subclavian-innominate junction (arrows). PSS: Paget schroetter syndrome.




Figure 2. Resected “offending” portion of the right first rib showing a tubercle (arrow) and abnormal costo-sternal joint corresponding to the extrinsic compression seen in [Figure 1](#).

Step 1 - port placement

Three 2-cm, nontrocar incisions are made [[Figures 5-7](#)]. Incision #1 is made at the 5th intercostal (IC) space

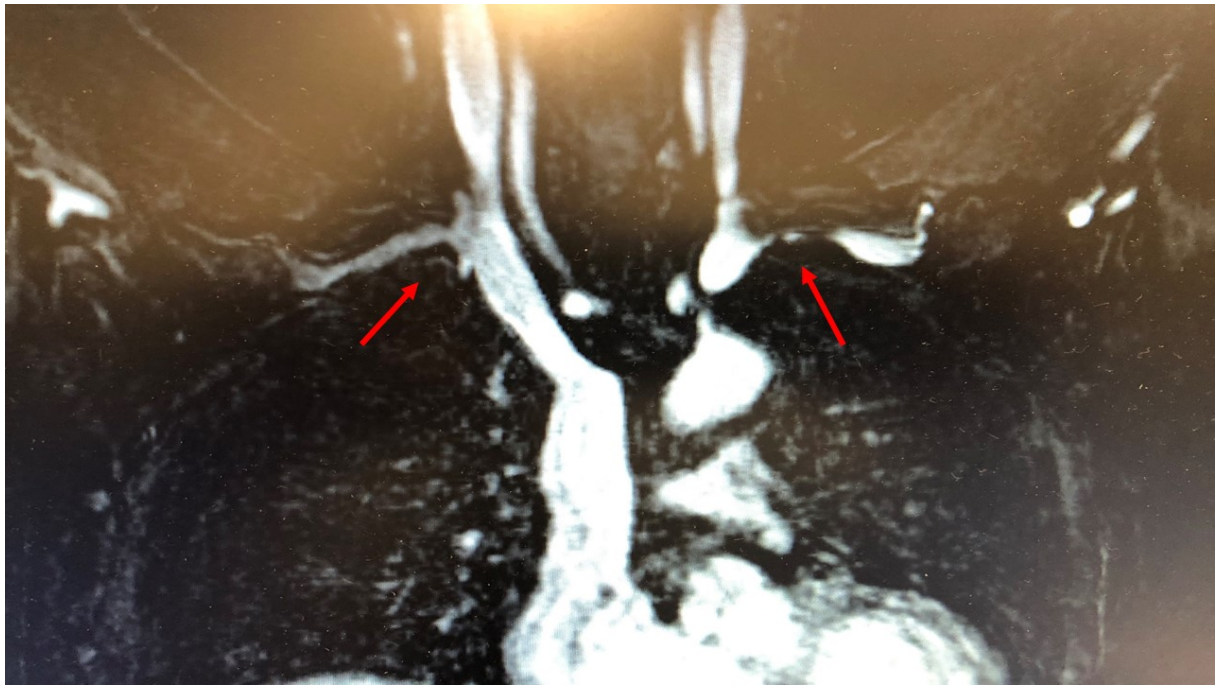


Figure 3. Magnetic Resonance Angiogram with elevation of the arms in a patient with DNTOS. There is bilateral compression off the subclavian-innominate junction (arrows). DNTOS: Disputed neurogenic thoracic outlet syndrome.



Figure 4. Resected "offending" portion of the right first rib showing a tubercle (arrow) and abnormal costo-sternal joint corresponding to the extrinsic compression seen in [Figure 3](#).

at the midaxillary line in the right chest. Incision #2 is made in the 4th IC space at the anterior axillary line. Incision #3 is made in the 4th IC space at the posterior axillary line. In the Left Chest, the port placement is

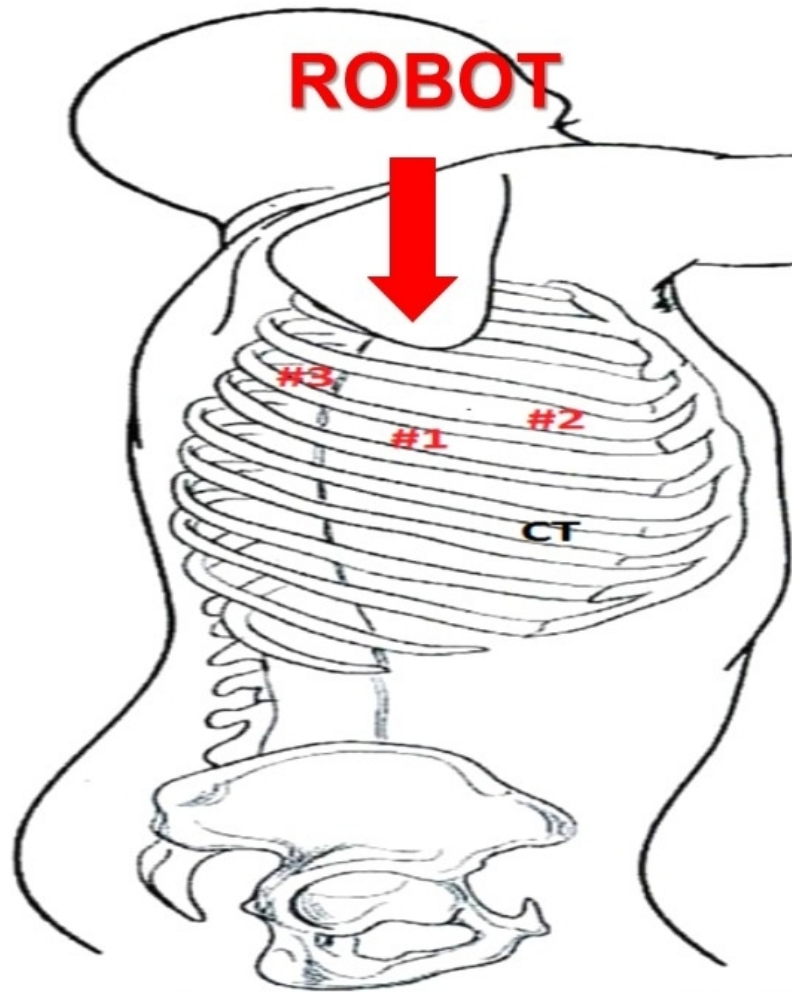


Figure 5. Patient in the left lateral decubitus position. Trocar sites are shown. The robot is brought over the head of the patient.

a mirror image of the right chest. A 1-cm incision #4 is made in the 6th intercostal space at the anterior axillary line. A retractor (Endopaddle Retractor; Auto Suture, Covidien incorporated, Mansfield, MA) is introduced through this incision and used to retract the lung inferiorly. At the end of the procedure, a chest drain (28 French tubes) is inserted through this incision.

Step 2 - dissection of the first rib

The surgical robot (da Vinci, Intuitive Surgical, Inc., Sunnyvale, CA) is positioned over the patient's head. The camera is placed in incision #1. For the placement of instruments, a 30-degree down-viewing camera is used. The right robotic arm with a hook cautery is positioned in incision #2. The left robotic arm with a grasper is positioned in incision #3. The assistant places a suction catheter through incision #3 under the left robotic arm. Next, the camera is turned to be 30-degree up viewing. The costo-asternal joint is identified. Then the pleura overlying the first rib is dissected. The edges of the rib are identified, as is the costo-sternal joint. Dissection of the pleura is carried just lateral to the subclavian artery. The lateral and posterior aspect of the rib with the associated neurologic structures is left intact.

Step 3 - division of the first rib

Next, the robotic arms are withdrawn. A 30-degree Video-assisted thoracic surgery camera is introduced,

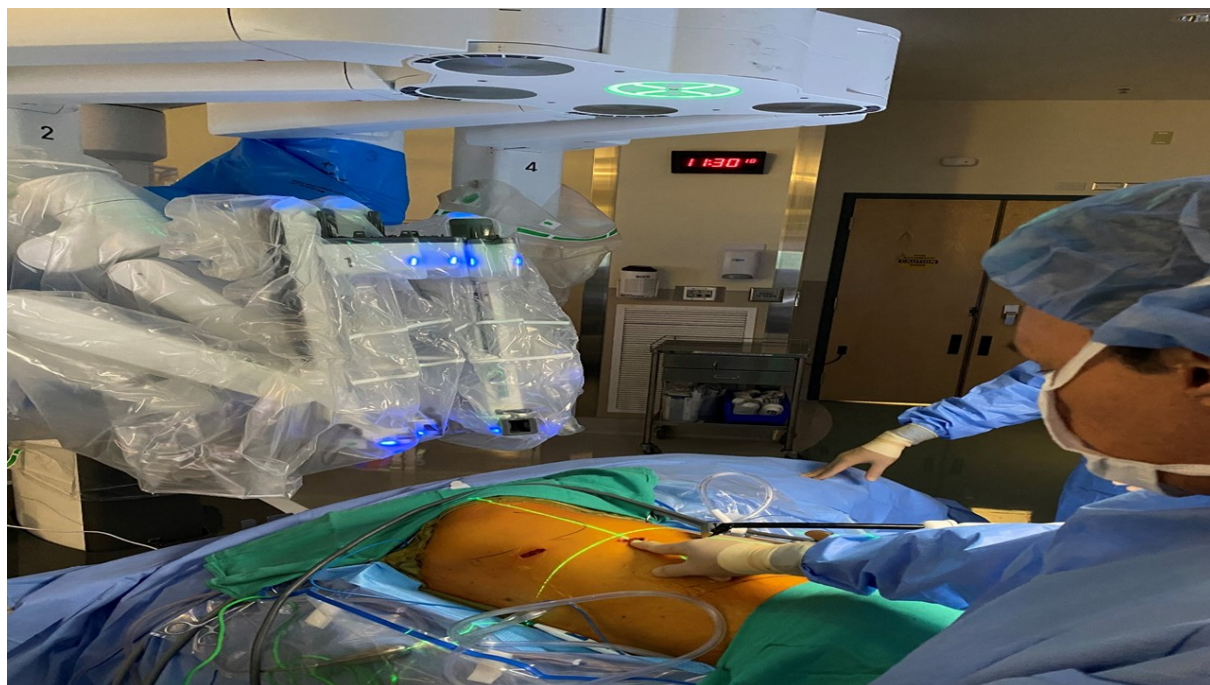

Figure 6. Patient in the left lateral decubitus position. Trocar sites are shown. The robot (da Vinci Xi) is brought over the head of the patient.

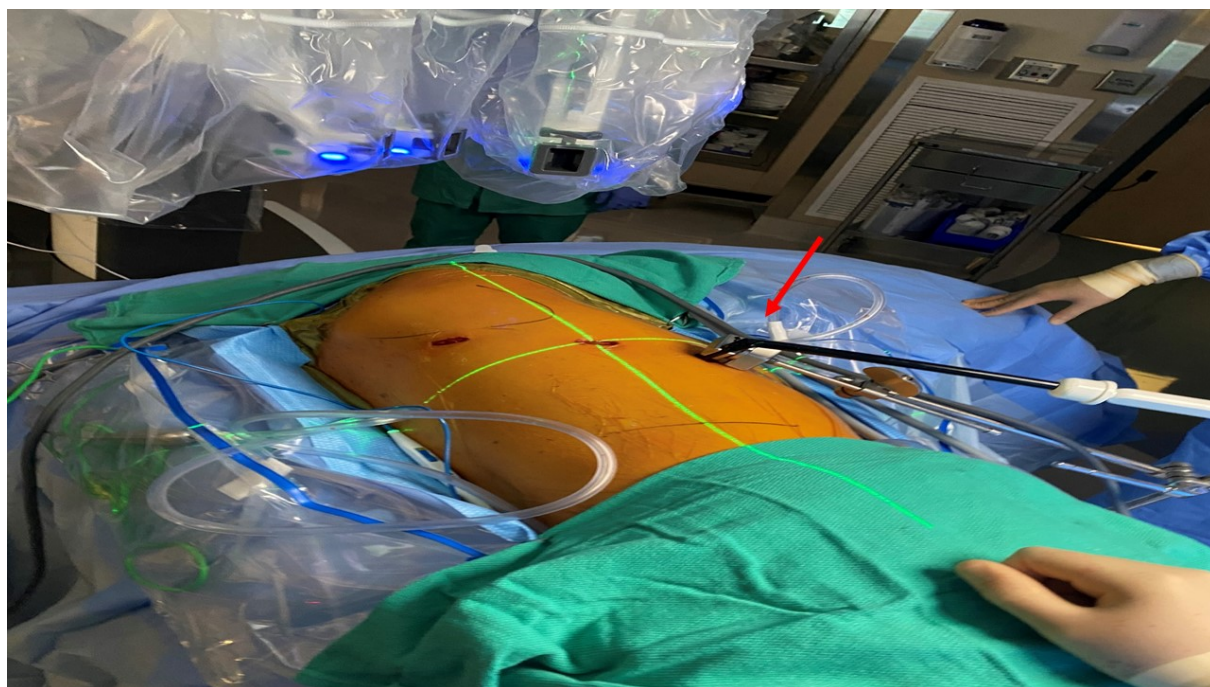


Figure 7. Patient in the left lateral decubitus position. The retractor (arrow) which is fixed to the bed is used to retract the lung inferiorly.

and the rib under the subclavian artery is divided using a 6-mm thoroscopic Kerrison bone cutter (Depuy Inc., Raynham, MA). The area under the subclavian artery, which corresponds with the subclavian groove, is the thinnest portion of the rib and is amenable to division with the bone cutter. The rib's division at its

midpoint allows it to be pivoted on the costo-sternal and costovertebral joints in a trap door configuration.

Step 4 - robotic dissection of the first rib and disarticulation of the costo-sternal joint

The robotic arms are replaced in the same ports. A 30-degree down-viewing robotic camera is introduced through incision #1, a hook cautery is placed in the right robotic arm in incision #2, and a second hook cautery is placed in the left robotic arm in incision #3. The hook in the left arm is used to put downward traction on the rib as the hook cautery (30 cut/30 coagulation setting) is used to dissect the first rib away from the subclavian vein, disconnect the scalene muscles from the rib, and disarticulate the rib from the sternal and times clavicular joint [Figure 8]. During this dissection, the table assistant places upward pressure on the tissues just superior to the edge of the first rib. This maneuver moves the vascular structures away from the bone and facilitates the dissection. The resected rib is removed through incision #2.

Step 5 - analgesia and chest closure

After completing the robotic procedure and undocking the robot, subpleural catheters are introduced for a prolonged paravertebral block of intercostals 2 through 8. This technique has been described previously^[9]. This strategy for pain control continues even after the patient is discharged from the hospital and gives the patient 10 days of local pain control.

RESULTS

The results of robotic first rib resection for PSS and NTOS have been reported previously^[6,7,8]. A total of 162 patients have undergone robotic first rib resection by our group. The first rib was removed en bloc, and the costo-sternal joint was disarticulated. Operative time was 87.6 min +/- 10.8 min. There were no intraoperative complications. Hospital stay ranged from 2 to 4 days with a median hospitalization of 3 days. There were no neurovascular complications. There was no mortality. In patients with neurologic symptoms, immediate relief of symptoms was seen in 71/79 patients (91%). In these patients, Quick DASH Scores (Mean +/- SEM) decreased from 60.3 +/- 2.1 preoperatively to 5 +/- 2.3 in the immediate postoperative period, and 3.5 +/- 1.1 at 6 months ($P < 0.0001$)^[10]. In patients with Paget-Schroetter syndrome, 31% required endovascular venoplasty to completely open the subclavian vein after relieving the extrinsic bony compression. In patients with PSS, at 3, 6, 12, and 24 months, in all patients, MRA with maneuvers showed relief of extrinsic compression and patency of the subclavian vein. Two years after robotic resection of the offending portion of the first rib and obtaining patency of the subclavian vein, all patients remained asymptomatic and had full function of the affected upper extremity.

DISCUSSION

Historically, TOS has been poorly understood^[11,12]. Invariably discussion about TOS leads to cervical ribs. Cervical ribs and associated bands can compress the brachial plexus and subclavian artery in the neck. However, cervical ribs and the associated bands extending from the cervical rib to the first rib are rare and not a common cause of TOS. In fact, it has been suggested that cervical rib disease should be classified separately from TOS. In an attempt to unify neurovascular symptoms related to the upper extremity, in 1956, Peet^[13] proposed the term "Thoracic Outlet Syndrome". Unfortunately, in 1958, Rob and Standeven used a similar term, "Thoracic Outlet Compression Syndrome", in their description of a series of patients with cervical ribs, arterial thrombosis, and distal gangrene of the upper extremity^[14]. This inadvertent association between patients who would best be classified as Cervical Rib Disease, and patients with problems related to the thoracic outlet, has resulted in a great deal of confusion among medical practitioners. In order to better understand the pathogenesis of TOS and design appropriate surgical procedures for the treatment of this disease, patients with neurovascular symptoms of the upper extremity who have been previously classified as TOS should be separated into Cervical Rib Disease, and Thoracic

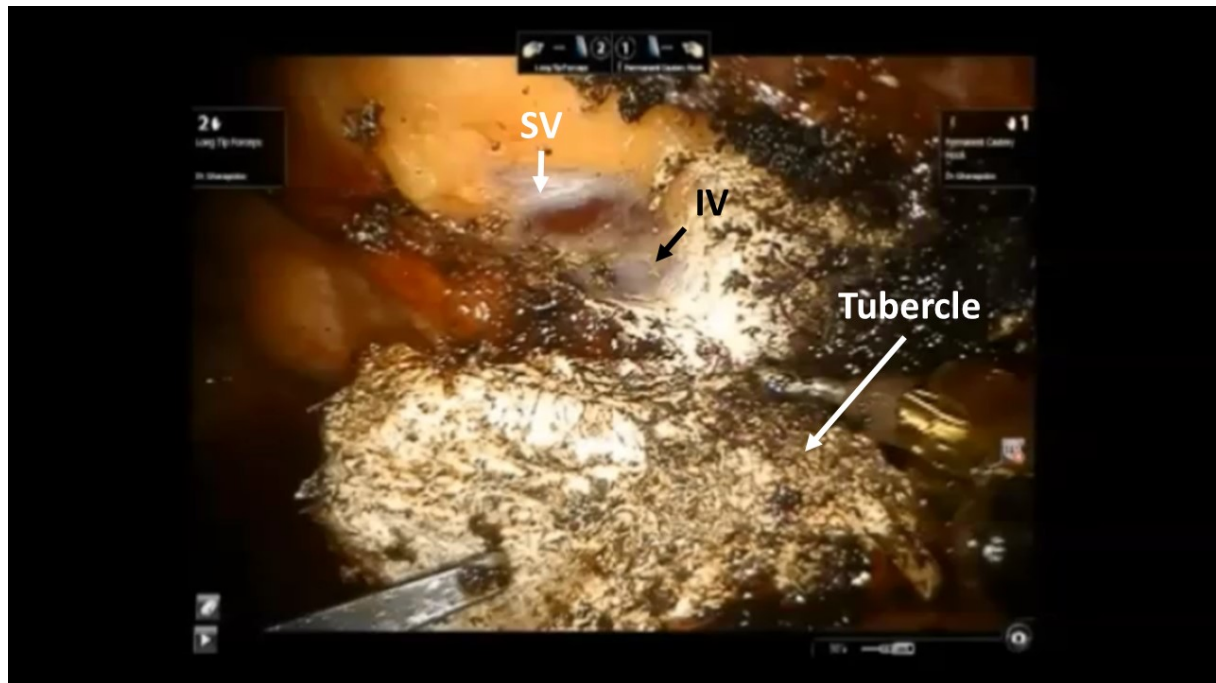


Figure 8. Intraoperative photograph during the robotic resection of the medial right first rib in a patient with Disputed Neurogenic TOS. The abnormal bony tubercle at the costo-sternal joint results in compression of the subclavian vein (SV) at its junction with the innominate vein (IV). TOS: Thoracic outlet syndrome.

Outlet Syndrome or “Subclavian Vein Compression Syndrome”. Gharagozloo *et al.*^[4] have proposed that symptoms which were previously classified as Neurogenic and Venous (PSS) TOS represent a variable symptomatic presentation of the compression of the subclavian vein by an abnormal bony tubercle at costo-sternal joint, which results in neurologic symptoms with mild compression (Neurogenic TOS) and thrombosis of the vein with prolonged compression (PSS). As a proof of concept, robotic resection of the medial aspect of the first rib and disarticulation of the costo-sternal joint has been associated with excellent results.

The robotic resection of the first rib has a number of technical challenges. These challenges can be divided into:

1. Anesthesia management: it is important to use hand ventilation with minimal mediastinal excursion during the robotic dissection. It prevents injury to the phrenic nerve or the superior vena cava.
2. Rib dissection: the costo-sternal joint for the first rib is invariably abnormal. The first rib should be identified at the costo-sternal joint and traced posteriorly. The first rib is covered with pleura and inner intercostal muscles. It is important to delineate the edges of the first rib clearly. In addition, the subclavian groove should be identified by tracing the subclavian artery from inside the chest. The Kerrison instrument is ideal for dividing the rib at the subclavian groove, where the rib is the thinnest. The anvil of the Kerrison instrument protects the subclavian artery while the blade divides the bone. The use of powered instruments or a Gigly saw has been described by Strother and Margolis^[15]. However, we have found the Kerrison to be the safest instrument for rib division.

3. Vascular injury: care should be taken to stay away from the subclavian vessels by remaining close to the bone. The surgical robot does not allow the use of two hook instruments. Therefore during this phase, the hook in the right robotic arm needs to be connected to an external cautery power source. The left hook pulls down on the bone, and the right hook “hugs” the bone. We have never had a vascular injury. However, we are always prepared and run team drills in a regular interval. Based on laboratory studies, the best way to control bleeding from the subclavian vein is to use the technique that we have previously described for control of major vascular injury during robotic lobectomy^[16].

Conclusion

Robotic surgical system allows for a minimally invasive, highly accurate approach to the disarticulation of the costo-sternal joint and resection of the abnormal portion of the first rib. The result following robotic first rib resection has been the best to date.

DECLARATIONS

Authors' contributions

Collected the data, designed and performed the procedures, and composed the manuscript: Gharagozloo F, Atiquzzaman N, Meyer M, Werden S

Availability of data and materials

Not applicable.

Financial support and sponsorship

None.

Conflicts of interest

All authors declared that there are no conflicts of interest.

Ethical approval and consent to participate

Not applicable.

Consent for publication

Not applicable.

Copyright

© The Author(s) 2021.

REFERENCES

1. Stewman C, Vitanzo PC Jr, Harwood MI. Neurologic thoracic outlet syndrome: summarizing a complex history and evolution. *Curr Sports Med Rep* 2014;13:100-6. DOI PubMed
2. Jones MR, Prabhakar A, Viswanath O, et al. Thoracic outlet syndrome: a comprehensive review of pathophysiology, diagnosis, and treatment. *Pain Ther* 2019;8:5-18. DOI PubMed PMC
3. Gharagozloo F, Meyer M, Tempesta B, Strother E, Margolis M, Neville R. Proposed pathogenesis of Paget-Schroetter disease: impingement of the subclavian vein by a congenitally malformed bony tubercle on the first rib. *J Clin Pathol* 2012;65:262-6. DOI PubMed
4. Gharagozloo F, Atiquzzaman N, Meyer M, Tempesta B, Werden S. Robotic first rib resection for thoracic outlet syndrome. *J Thorac Dis* 2020. DOI
5. Kobayashi S, Takeno K, Miyazaki T, et al. Effects of arterial ischemia and venous congestion on the lumbar nerve root in dogs. *J Orthop Res* 2008;26:1533-40. DOI PubMed
6. Gharagozloo F, Meyer M, Tempesta B, Gruessner S. Robotic transthoracic first-rib resection for Paget-Schroetter syndrome. *Eur J Cardiothorac Surg* 2019;55:434-9. DOI PubMed
7. Gharagozloo F, Meyer M, Tempest B, Weden S. Robotic first rib resection for thoracic outlet syndrome. *Surg Technol Int* 2020;36:239-44. PubMed
8. Gharagozloo F, Meyer M, Tempesta BJ, Margolis M, Strother ET, Tummala S. Robotic en bloc first-rib resection for Paget-Schroetter

- disease, a form of thoracic outlet syndrome: technique and initial results. *Innovations (Phila)* 2012;7:39-44. DOI PubMed
9. Gharagozloo F. Pain management following robotic thoracic surgery. *Mini-invasive Surg* 2020;4:8. DOI
 10. Matheson LN, Melhorn JM, Mayer TG, Theodore BR, Gatchel RJ. Reliability of a visual analog version of the QuickDASH. *J Bone Joint Surg Am* 2006;88:1782-7. DOI PubMed
 11. Peek J, Vos CG, Ünlü Ç, van de Pavoordt HDWM, van den Akker PJ, de Vries JPM. Outcome of surgical treatment for thoracic outlet syndrome: systematic review and meta-analysis. *Ann Vasc Surg* 2017;40:303-26. DOI PubMed
 12. Peek J, Vos CG, Ünlü Ç, Schreve MA, van de Mortel RHW, de Vries JPM. Long-term functional outcome of surgical treatment for thoracic outlet syndrome. *Diagnostics (Basel)* 2018;8:7. DOI PubMed PMC
 13. Peet RM, Henriksen JD, Anderson TP, Martin GM. Thoracic-outlet syndrome: evaluation of a therapeutic exercise program. *Proc Staff Meet Mayo Clin* 1956;31:281-7. PubMed
 14. ROB CG, STANDEVEN A. Arterial occlusion complicating thoracic outlet compression syndrome. *Br Med J* 1958;2:709-12. DOI PubMed PMC
 15. Strother E, Margolis M. Robotic first rib resection. *Thoracand Cardiovasc Surg* 2015;20:176-88. DOI
 16. Gharagozloo F, Meyer M. Technique of robotic lobectomy III: control of major vascular injury, the 5 “P”’s. *Mini-invasive Surg* 2020;4:57. DOI